

Dentigerous Cyst in the Children: A Case Report

Gotmare Swati Shrikant, Sourabh Milindraj Savale, Treville Pereira, Avinash Tamgadge, Sandhya Tamgadge, Siddhesh Birje

ABSTRACT

Introduction: Dentigerous cysts are the second most common developmental odontogenic cysts of the jaw, arising from impacted, embedded or unerupted permanent teeth. They apparently develop by accumulation of fluid between the reduced enamel epithelium and the tooth crown of an unerupted tooth. There is usually no pain or discomfort associated with the cyst unless there is an acute inflammatory exacerbation.

Case Presentation: The purpose of this case report is to present a case of a dentigerous cyst with an unusual presentation in a 6-year-old child came with the swelling over right back region of the jaw which was asymptomatic appearing bony hard on palpation. Radiography showing unilocular radiolucency with an unerupted mandibular tooth crown is seen. Histology revealed H & E-stained section showing non keratinized epithelium 2-3 cell layer thick underlying connective tissue wall is loose fibrocellular with mild to moderate inflammatory cells infiltrate comprising of plasma cells, lymphocytes & numerous blood vessels and the definitive diagnosis of Dentigerous cyst was made. Management is done using enucleation of the cystic space with curettage & extraction of associated teeth.

Conclusion: Management of odontogenic lesions, such as dentigerous cysts in children, presents an unparalleled challenge to general and pediatric dentists alike. A thorough understanding of the nature of the lesion backed by good clinical history and state-of-art radiography can go a long way in helping the clinician to arrive at the correct therapeutic choice of approach, ameliorate the condition in the best long-term interests of the young patient.

Keywords: Cyst, swelling, unerupted tooth, marsupialization.

Oral and Maxillofacial Pathology Journal (2022): <https://www.ompj.org/archives>.

INTRODUCTION

Jaw lesions affect children in a variety of ways, ranging from developmental abnormalities to inflammatory conditions. Dentigerous cysts are odontogenic cysts associated with an erupted or developing tooth, most typically the mandibular third molars; the maxillary canines, maxillary third molars, and occasionally the central incisors are also frequently afflicted.¹

By careful evaluation and with precise clinical and radiological studies, clinicians may be able to arrive at an accurate diagnosis and address the implicated etiologies.²

Here, we report a case of a dentigerous cyst in a 6-year-old male patient and its management. These cysts form between the enamel epithelium and the crown of the associated tooth's enamel. It was inflammatory based on the patient's young age and features, including a necrotic primary molar pus-filled cystic mass.

CASE REPORT

A 6-year-old male child was reported to D Y Patil University School of Dentistry, Navi Mumbai, with a chief complaint of swelling over the lower right back region of the jaw, which was

Dept. of Oral and Maxillofacial Pathology and Microbiology, D Y Patil University School of Dentistry, Sector 7, Nerul, Navi Mumbai, Maharashtra, India, Pin-4000706

Corresponding author: Dr.Gotmare Swati Shrikant, Department of Oral and Maxillofacial Pathology, D Y Patil University School of Dentistry, Sector 7, Nerul, Navi Mumbai, Maharashtra, India, Pin-4000706. Email- swatishrikant2003@gmail.com

How to cite this article: Shrikant GS, SavaleSM, Pereira T, Tamgadge A, Tamgadge S, Birje S. Dentigerous Cyst In The Children: A Case Report. Oral MaxillofacPathol J 2022; 13(2): page no. 183-185

Source of Support: Nil

Conflict of Interest: None

painless (Fig. 1). The medical history was not significant, the patient was apparently healthy. No history of trauma, no episodes of pain or discharge from the site were reported by the patient. Palpation revealed bony hard swelling with a smooth surface in 85 of 46 regions. The swelling was non-tender with no pulsations

and no eggshell cracking. No rise in the local temperature and no secondary changes were evident. Lymph node examination revealed no pathology.

In 85,46 apical regions intraosseous, apparently 1 cm 1.2 cm in size, orthopantomography revealed unilocular well-defined radiolucency associated with an unerupted mandibular tooth crown (Fig. 2). Lateral and occlusal views showed expansion and thinning of the buccal wall with no signs of root resorption in adjacent teeth (Fig. 3).

The cystic lesion was aspirated & suppurative fluid was evacuated. A provisional diagnosis of dentigerous cyst was made on above mentioned findings.

The case was referred to department of oral and maxillofacial surgery of our respective institute, oral surgeon elected to perform a punch biopsy. On gross examination of the tissue specimen, showed single cystic sac measuring 1.1x1.2x1 cm in dimension, oval in shape, white and yellowish in color, and soft in consistency.

Histopathologically, the H and E sections showed non keratinized epithelium which is 2-3 cell layers thick with underlying connective tissue, connective tissue wall loose fibrocellular with mild to moderate inflammatory cell infiltrate, comprising of plasma cells, lymphocytes, and numerous blood vessels. The definitive diagnosis of dentigerous cyst was confirmed by observation and examination.

Under local anesthesia, the deciduous second molar and permanent first molar were extracted. A preventive approach can be followed to preserve the developing mandibular erupting tooth. Enucleation of the entire cystic lesion with curettage and normal saline irrigation was done, followed by suitable sutures, and the specimen sent for histopathological examination. No complications were observed. Patient was discharged & advised regular follow-up (2 weeks interval).

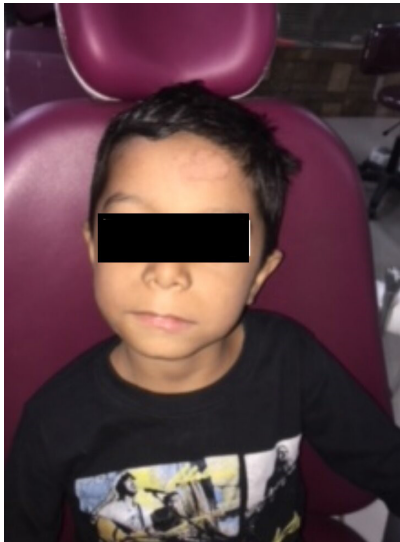

Fig. 1: Extra-oral view showing facial asymmetry (swelling on right side)

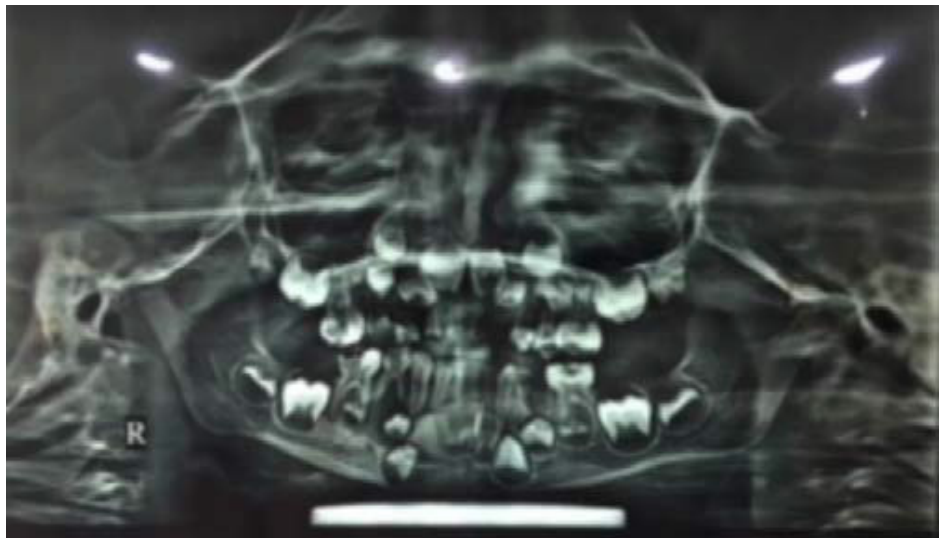


Fig. 2: Orthopantomography showing radiolucent cyst embedding crown of developing tooth & crown over crown appearance in lower right back region of jaw below 85, 46.

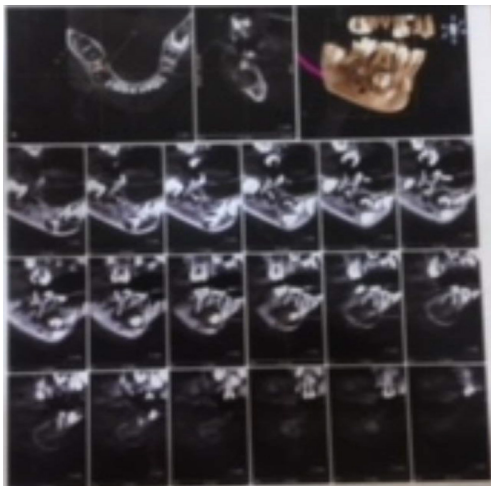

Fig. 3: Lateral & occlusal view showing bony involvement & expansion of buccal plate in lower right back region of jaw.

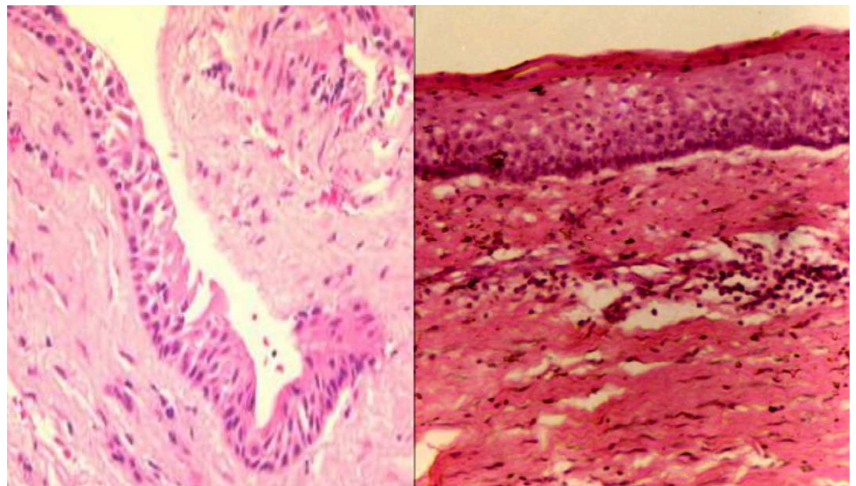


Fig. 4: Dentigerous cyst.

DISCUSSION

Dentigerous cysts were divided into developmental and inflammatory kinds by Benn and Altini in 1996. The majority of mandibular third molars are affected by developmental dentigerous cysts, which are caused by impacted mature teeth. The inflammatory type, on the other hand, affects a developing permanent tooth and is caused by an infected necrotic primary tooth stimulating the immature germ follicle of the permanent tooth.³

The type of dentigerous cyst, in this case, was inflammatory based on the patient's young age and features, including a necrotic primary molar pus-filled cystic mass. Enucleation was chosen as, below the crown embedded in the cyst, there is one more developing tooth crown (crown over crown appearance). One, which is below, was allowed to develop and erupt naturally.³

According to Bloch, the overlying necrotic deciduous tooth is the source of the dentigerous cyst. The periapical infection that results will spread to an unerupted permanent successor follicle, resulting in inflammatory exudates and the creation of a dentigerous cyst.⁶

When it comes to making a definitive diagnosis, a histologic examination is always the gold standard. Several treatment options for removing dentigerous cysts are suggested, with the goal of complete pathology elimination and dentition preservation with minimal surgical intervention.⁷

Marsupialization, also known as decompression, is a procedure for relieving intracystic pressure by creating an auxiliary cavity. Hyomoto et al. (2003) discovered that marsupialization assisted the natural eruption of the concerned tooth in dentigerous cysts in 72.4 percent of cases, implying that it should be considered as a first line of treatment in paediatric patients. Because the dental follicle surrounding an unerupted tooth's crown is normally bordered by a thin layer of decreased enamel epithelium, microscopic characteristics alone may make it difficult to distinguish a small dentigerous cyst from a normal or larger dental follicle.⁴

Dentigerous cysts, as opposed to radicular cysts or odontogenic keratocyst, appear to be more likely to cause root resorption of adjacent teeth. Cysts that form in a growing adolescent will grow considerably faster than in an adult. Treatment for a dentigerous cyst is determined by its size, location, and deformity; it frequently necessitates varied bone removal to guarantee entire cyst removal, especially in the case of big cysts. If the cyst is small, it can be enucleated, but a larger cyst may require marsupialization to be completely removed. Whenever a young patient's teeth are most

important to them and the lesion is isolated, marsupialization is the choice of treatment.⁵

In such situations, proper decision-making in selecting the appropriate treatment modality plays a crucial role in the prognosis of the overall therapy. For the present case, we considered all possible modalities by taking into account factors such as age, gender, location, size, as well as the patient's socioeconomic status. When treating a dentigerous cyst, because it is difficult to maintain patency in a bony lesion.¹

CONCLUSION

Management of odontogenic lesions, such as dentigerous cysts in children, presents an unparalleled challenge to general and paediatric dentists alike. Coupled with the need for appropriate behavior management and the delicate balance between the primary and developing permanent dentitions, these warrant a highly meticulous approach on the part of every clinician involved in providing dental care to such child patients. A thorough understanding of the nature of the lesion backed by good clinical history and state-of-the-art radiography can go a long way in helping the clinician to arrive at the correct therapeutic choice of approach and ameliorate the condition in the best long-term interests of the young patient.

REFERENCES

1. Arjona-Amo M, Serrera-Figallo MA, Hernández-Guisado JM, et al. Conservative management of dentigerous cysts in children. *Journal of Clinical and Experimental Dentistry*. 2015 Dec;7(5):e671-4. DOI: 10.4317/jced.52248. PMID: 26644847; PMCID: PMC4663073.
2. Hegde, R. J., Khare, S. S., & Devrukhkar, V. N. (2013). Dentigerous cyst in a young child: clinical insight and a case report. *Journal of the Indian Society of Pedodontics and Preventive Dentistry*, 31(3), 209–211. <https://doi.org/10.4103/0970-4388.117967>
3. Alnofaie, H., Alomran, O., Ababtain, R., & Alomar, A. (2019). Spontaneous Eruption of a Deeply Impacted Premolar After Conservative Treatment of an Associated Dentigerous Cyst: A Case Report. *Cureus*, 11(12), e6414. <https://doi.org/10.7759/cureus.6414>
4. Arakeri G, Rai KK, Shivakumar HR, Khaji SI. A massive dentigerous cyst of the mandible in a young patient: a case report. *Plast Aesthet Res* 2015;2:294-298. <http://dx.doi.org/10.4103/2347-9264.165439>
5. Jindal G, Batra H, Kaur S, Vashist D. Dentigerous cyst associated with mandibular 2nd molar: an unusual entity. *J Maxillofac Oral Surg*. 2015;14(Suppl 1):154-157. doi:10.1007/s12663-012-0393-3
6. Pramod, D. S., & Shukla, J. N. (2011). Dentigerous cyst of maxilla in a young child. *National journal of maxillofacial surgery*, 2(2), 196–199. <https://doi.org/10.4103/0975-5950.94481>
7. Demiriz, L., Misir, A. F., & Gorur, D. I. (2015). Dentigerous cyst in a young child. *European journal of dentistry*, 9(4), 599–602. <https://doi.org/10.4103/1305-7456.172619>